



Case Report

Pneumomediastinum Following a Routine Dental Filling in an Adolescent: A Rare Pediatric Case Report

Şeyma Dilek ^{a,*} , Ahu Bayar ^b, Furkan Çolak ^a , Ethem İlhan ^c , Şükran Duman ^c , Hüseyin Dağ ^d 

^a Department of Pediatrics, Gaziosmanpaşa Training and Research Hospital, Istanbul, Turkey

^a Department of Pediatric Surgery, Gaziosmanpaşa Training and Research Hospital, Istanbul, Turkey

^c Department of Otorhinolaryngology Head and Neck Surgery, Gaziosmanpaşa Training and Research Hospital, Istanbul, Turkey

^d Department of Pediatrics, Prof. Dr. Cemil Taşcıoğlu City Hospital, Istanbul, Turkey

ARTICLE INFO

Article history:

Received 25 February 2026

Received in revised form 04

May 2026

Accepted 19 May 2026

Keywords:

Pneumomediastinum

Dental filling

Adolescent

ABSTRACT

Pneumomediastinum is defined as the presence of free air within the mediastinal cavity and most commonly occurs as a result of spontaneous alveolar rupture or thoracic trauma. Iatrogenic pneumomediastinum secondary to dental procedures is exceedingly rare, particularly in the pediatric population. High-speed air-turbine dental drills may introduce pressurized air into disrupted dentoalveolar tissues, enabling air to dissect along cervical fascial planes and track into the mediastinum through the submandibular and retropharyngeal spaces. In this report, we present a rare case of pneumomediastinum developing after a routine dental filling in an adolescent patient.

© 2026 The Authors. Published by Iberoamerican Journal of Medicine. This is an open access article under the CC BY license (<http://creativecommons.org/licenses/by/4.0/>).

* Corresponding author.

E-mail address: seymadilek0@gmail.com

ISSN: 2695-5075 / © 2026 The Authors. Published by Iberoamerican Journal of Medicine. This is an open access article under the CC BY license (<http://creativecommons.org/licenses/by/4.0/>).

<https://doi.org/10.53986/ibjm.2026.0014>

Neumomediastino tras un empaste dental rutinario en un adolescente: un caso clínico pediátrico poco frecuente

INFO. ARTÍCULO

Historia del artículo:
Recibido 25 Febrero 2026
Recibido en forma revisada 04
Mayo 2026
Aceptado 19 Mayo 2026

Palabras clave:
Neumomediastino
Empaste dental
Adolescente

RESUMEN

El neumomediastino se define como la presencia de aire libre en la cavidad mediastínica y suele producirse como consecuencia de una ruptura alveolar espontánea o un traumatismo torácico. El neumomediastino iatrogénico secundario a procedimientos dentales es extremadamente raro, sobre todo en la población pediátrica. Los taladros dentales de turbina de aire de alta velocidad pueden introducir aire a presión en los tejidos dentoalveolares dañados, lo que permite que el aire se disemine a lo largo de los planos fasciales cervicales y se introduzca en el mediastino a través de los espacios submandibular y retrofaríngeo. En este informe, presentamos un caso raro de neumomediastino que se desarrolló tras un empaste dental rutinario en un paciente adolescente.

© 2026 Los Autores. Publicado por Iberoamerican Journal of Medicine. Éste es un artículo en acceso abierto bajo licencia CC BY (<http://creativecommons.org/licenses/by/4.0/>).

HOW TO CITE THIS ARTICLE: Dilek S, Bayar A, Çolak F, İlhan E, Duman S, Dağ H. Pneumomediastinum Following a Routine Dental Filling in an Adolescent: A Rare Pediatric Case Report. Iberoam J Med. 2026. doi: 10.53986/ibjm.2026.0014. [Ahead of Print].

1. INTRODUCTION

Pneumomediastinum is defined as the presence of free air within the mediastinal space and most commonly results from spontaneous alveolar rupture or airway injury [1]. It may occur spontaneously or secondary to trauma, surgical interventions, or other iatrogenic causes. High-speed air-turbine drills used during dental procedures can introduce pressurized air into disrupted dentoalveolar tissues, leading to pneumomediastinum [2]. Once forced into the soft tissues, air may track along cervical fascial planes and extend into the mediastinum [3]. The submandibular, retropharyngeal, and parapharyngeal spaces serve as potential anatomical pathways for this air dissemination [4]. Although the majority of cases are spontaneous or trauma-related, rare instances following dental interventions have been described and may lead to serious complications such as sepsis, air embolism, or cardiac compression [5]. Most reported cases occur after facial trauma, tracheostomy, or thoracic surgery, whereas pneumomediastinum following routine dental fillings remains exceedingly uncommon [6]. Careful clinical observation is essential in patients with pneumomediastinum. Uncomplicated cases typically resolve with conservative management, including rest, analgesia, and avoidance of Valsalva maneuvers. Short-term hospital observation (24–48 hours) is recommended to allow early detection of potential airway compromise due to progressive air dissection [7, 8].

We present a rare pediatric case of pneumomediastinum following a routine dental filling procedure.

2. CASE REPORT

A 16-year-old previously healthy girl presented to the pediatric emergency department with sudden facial and neck swelling, chest tightness, and shortness of breath that developed six hours after a routine dental filling procedure. Her medical and family histories were unremarkable.

On physical examination, her heart rate was 101 beats/min, blood pressure 100/70 mmHg, respiratory rate 22 breaths/min, temperature 36.8°C, and oxygen saturation (SpO₂) 94% on room air. Palpable subcutaneous crepitus was noted in the cervical, axillary, and anterior chest regions, accompanied by bilateral cervical swelling.

Laboratory investigations were within age-appropriate reference ranges. Arterial blood gas analysis showed: pH 7.38, PaCO₂ 42.3 mmHg, PaO₂ 80 mmHg, HCO₃⁻ 24.5 mmol/L, Na⁺ 138.5 mmol/L, and K⁺ 3.46 mmol/L.

Chest radiography revealed extensive subcutaneous emphysema extending into the cervical region (Figure 1). Cervical computed tomography demonstrated air tracking along the deep fascial planes. Thoracic CT confirmed extensive subcutaneous emphysema and pneumomediastinum within the anterior mediastinum (Figure 2).

There was no history of forceful vomiting or retching suggestive of Boerhaave syndrome. Additionally, thoracic imaging did not reveal mediastinal fluid collection or evidence of esophageal perforation, and the patient remained clinically stable without signs of systemic toxicity.

Consultations with otolaryngology and pediatric surgery were obtained. Both services recommended conservative management, and surgical intervention was deemed unnecessary. The patient was hospitalized and treated conservatively with bed rest, activity restriction, analgesia, and intravenous broad-spectrum antibiotics for three days. By the fourth hospital day, her symptoms had markedly improved. Repeat imaging demonstrated complete resolution. A follow-up posteroanterior chest radiograph obtained prior to discharge confirmed full radiologic recovery (Figure 3). The patient was discharged in good clinical condition.

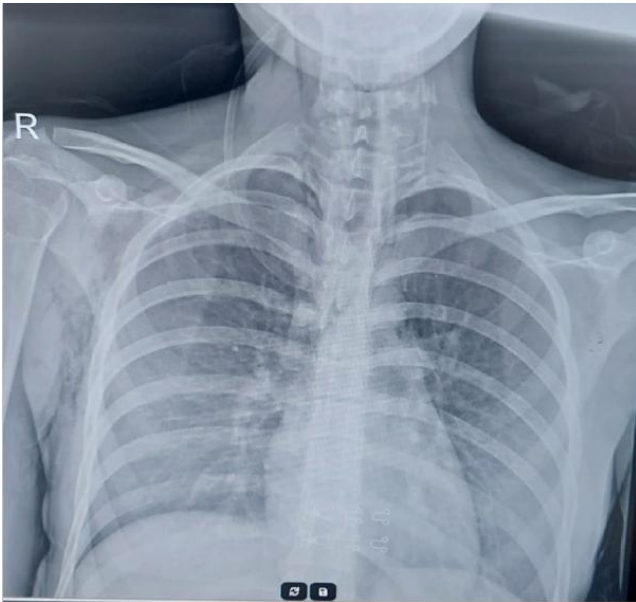


Figure 1: Posteroanterior chest radiograph demonstrating extensive cervicofacial subcutaneous emphysema, characterized by radiolucent air outlining the soft tissues of the neck, without evidence of pneumothorax.

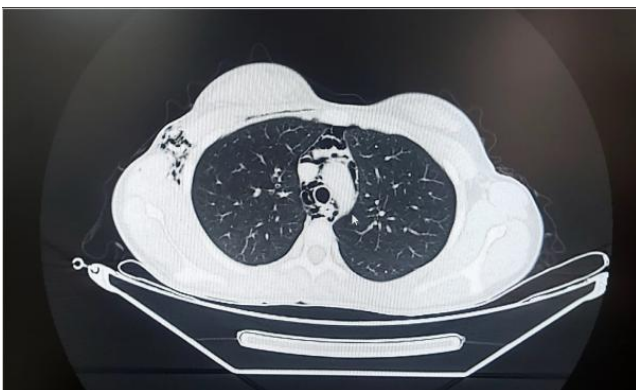

Figure 2: Thoracic computed tomography demonstrated extensive subcutaneous emphysema and pneumomediastinum, predominantly localized within the anterior mediastinum.

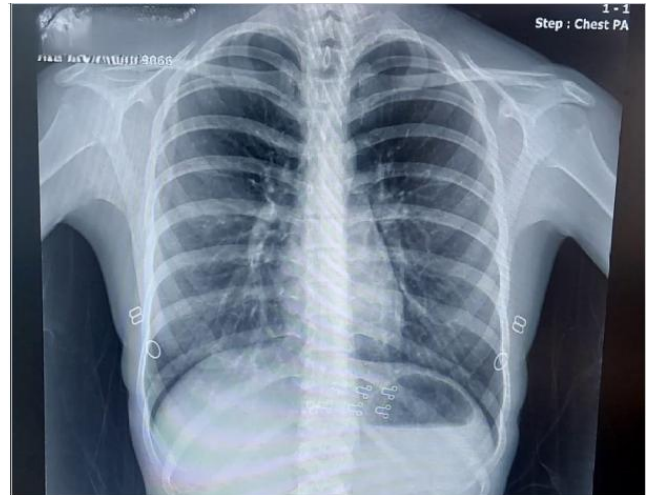


Figure 3: Follow-up posteroanterior chest radiograph showing complete radiographic resolution.

3. DISCUSSION

Subcutaneous and mediastinal emphysema associated with dental procedures have been reported in the literature for more than a century. The condition is most commonly linked to the use of high-pressure air-turbine drills, which can introduce pressurized air into disrupted dentoalveolar tissues and facilitate its spread along cervical fascial planes.

Peters et al. reviewed cases of subcutaneous emphysema following third molar extraction published since 2010 and reported mediastinal extension in 20 of 26 cases (77%) [9]. However, this proportion reflects selected reported cases rather than the true incidence among all third molar extractions or dental procedures overall, as publication bias may favor more extensive presentations.

Similarly, Tegenbosch et al. conducted a comprehensive review of dental procedure-related subcutaneous emphysema cases reported between 1973 and 2023, identifying 44 patients in the literature [10]. In their analysis, all cases were managed conservatively without the need for surgical intervention, and clinical outcomes were uniformly favorable. Pediatric cases remain particularly uncommon. In a case series, Durukan et al. described six adult patients who developed pneumomediastinum following dental treatment [11]. Ocakcioğlu et al. documented pneumomediastinum occurring in a young patient subsequent to dental extraction [12]. Similarly, Gerçel et al. described a case of non-traumatic pneumomediastinum in a 15-year-old male patient after endodontic (root canal) therapy [13].

Pathophysiologically, dental procedure-related pneumomediastinum differs from spontaneous forms. In spontaneous pneumomediastinum, alveolar rupture allows

air to dissect along bronchovascular sheaths toward the mediastinum (Macklin effect) [14]. In contrast, dental cases result from direct insufflation of air into cervical fascial planes, with subsequent extension into the mediastinum through the submandibular, parapharyngeal, or retropharyngeal spaces.

Management is primarily conservative. Most uncomplicated cases resolve with rest, analgesia, and avoidance of Valsalva maneuvers [7]. Supplemental oxygen may enhance nitrogen washout and accelerate reabsorption of free air [1]. Although there was no clinical or laboratory evidence of infection in our patient, prophylactic antibiotics were administered due to the potential risk of secondary infection and mediastinitis from oral flora tracking along fascial planes. However, the necessity of antibiotic use in such cases remains controversial in the current literature [3]. Close clinical observation is recommended to identify rare but potentially serious complications such as airway compromise, tension pneumomediastinum, or air embolism [5].

Our case adds to the limited pediatric literature and demonstrates that even routine dental procedures, including simple fillings, may lead to pneumomediastinum in the absence of overt trauma. Early recognition and appropriate conservative management can result in complete recovery without invasive intervention.

4. CONFLICT OF INTERESTS

The authors have no conflict of interest to declare. The authors declared that this study has received no financial support.

5. REFERENCES

1. Kouritas VK, Papagiannopoulos K, Lazaridis G, Baka S, Mpoukouvias I, Karavasilis V, et al. Pneumomediastinum. *J Thorac Dis.* 2015;7(Suppl 1):S44-9. doi: 10.3978/j.issn.2072-1439.2015.01.11.
2. McKenzie WS, Rosenberg M. Iatrogenic subcutaneous emphysema of dental and surgical origin: a literature review. *J Oral Maxillofac Surg.* 2009;67(6):1265-8. doi: 10.1016/j.joms.2008.12.050.
3. Maunder RJ, Pierson DJ, Hudson LD. Subcutaneous and mediastinal emphysema. Pathophysiology, diagnosis, and management. *Arch Intern Med.* 1984;144(7):1447-53.
4. Arai I, Aoki T, Yamazaki H, Ota Y, Kaneko A. Pneumomediastinum and subcutaneous emphysema after dental extraction detected incidentally by regular medical checkup: a case report. *Oral Surg Oral Med Oral Pathol Oral Radiol Endod.* 2009;107(4):e33-8. doi: 10.1016/j.tripleo.2008.12.019.
5. Newcomb AE, Clarke CP. Spontaneous pneumomediastinum: a benign curiosity or a significant problem? *Chest.* 2005;128(5):3298-302. doi: 10.1378/chest.128.5.3298.
6. Rawlinson RD, Negmadjanov U, Rubay D, Ohanian L, Waxman J. Pneumomediastinum After Dental Filling: A Rare Case Presentation. *Cureus.* 2019;11(9):e5593. doi: 10.7759/cureus.5593.
7. Sahni S, Verma S, Grullon J, Esquire A, Patel P, Talwar A. Spontaneous pneumomediastinum: time for consensus. *N Am J Med Sci.* 2013;5(8):460-4. doi: 10.4103/1947-2714.117296.
8. Campbell-Silva S, Campbell-Quintero S, Díaz-Rodríguez DC, Campbell-Quintero S, Castro-González I. Spontaneous Pneumomediastinum: A Narrative Review Offering a New Perspective on Its Definition and Classification. *Cureus.* 2025;17(4):e81822. doi: 10.7759/cureus.81822.
9. Peters M, Shall F, Evrard L. Pneumomediastinum after Third Molar Extraction: Case Report, Physiopathology, and Literature Review. *Case Rep Dent.* 2023;2023:4562710. doi: 10.1155/2023/4562710.
10. Matsushita R, Ehara J, Yamaba T, Nasu K, Sugita Y, Hiraoka E. Subcutaneous Emphysema and Pneumomediastinum Following a Dental Procedure without Tooth Extraction: A Case Report and Literature Review. *Intern Med.* 2026;65(7):1074-8. doi: 10.2169/internalmedicine.5750-25.
11. Durukan P, Salt O, Ozkan S, Durukan B, Kavalci C. Cervicofacial emphysema and pneumomediastinum after a high-speed air drill endodontic treatment procedure. *Am J Emerg Med.* 2012;30(9):2095.e3-6. doi: 10.1016/j.ajem.2012.01.006.
12. Ocakcioglu I, Koyuncu S, Kupeli M, Bol O. Pneumomediastinum after Tooth Extraction. *Case Rep Surg.* 2016;2016:4769180. doi: 10.1155/2016/4769180.
13. Gerçel G, Gülçin N, Mutuş M, Aksu B, Özatman E, Ulukaya Durakbaşa Ç, et al. Pneumomediastinum after dental treatment. 34th Annual Congress of Turkish Pediatric Surgical Association. 2016. Available from: <https://www.bildirim.org/bildiri-goster/cocukcer2016/3625>
14. Macklin MT, Macklin CC. Malignant interstitial emphysema of the lungs and mediastinum as an important occult complication in many respiratory diseases. *Medicine (Baltimore).* 1944;23:281-358.