



Case Report

The Association of SGLT-2 inhibitors (Empagliflozin) with the development of hypernatremic dehydration: a case report

Diana Alegre-González ^{a,*} , Sandra García-Guerreros ^a, Sara Martínez-Hernández ^a, Ana Yasmina Brito-Díaz ^a, Marta Casañas-Martínez ^a, Ramón Baeza-Trinidad ^a 

^a Department of Internal Medicine, Hospital San Pedro, Logroño, Spain

ARTICLE INFO

Article history:

Received 04 May 2024

Received in revised form 01

August 2024

Accepted 09 October 2024

Keywords:

SGLT-2 inhibitors

Empagliflozin

Hypernatremia

Dehydration

ABSTRACT

Sodium-Glucose-Cotransporter -2 inhibitors (SGLT2 inhibitors) are a new class of drugs that reduce blood glucose levels by increasing glucose excretion and lowering blood pressure through natriuresis and plasma volumen contraction. Due to their beneficial effects, they are currently used in treatment of both diabetes mellitus and heart failure, leading to widespread use in recent years. Here, we present a case of a patient who experienced severe hypernatremic dehydration related to the initiation of treatment with iSGLT2 inhibitors.

© 2025 The Authors. Published by Iberoamerican Journal of Medicine. This is an open access article under the CC BY license (<http://creativecommons.org/licenses/by/4.0/>).

* Corresponding author.

E-mail address: dalegglez@gmail.com

ISSN: 2695-5075 / © 2025 The Authors. Published by Iberoamerican Journal of Medicine. This is an open access article under the CC BY license (<http://creativecommons.org/licenses/by/4.0/>).

<https://doi.org/10.53986/ibjm.2025.0001>

Asociación de inhibidores de SGLT-2 (Empagliflozina) con el desarrollo de deshidratación hipernatrémica: reporte de un caso

INFO. ARTÍCULO

Historia del artículo:
Recibido 04 Mayo 2024
Recibido en forma revisada 01 Agosto 2024
Aceptado 09 Octubre 2024

Palabras clave:
Inhibidores SGLT-2
Empagliflozina
Hipernatremia
Deshidratación

RESUMEN

Los inhibidores del cotransportador de sodio-glucosa-2 (inhibidores de iSGLT2) son una nueva clase de fármacos que reducen los niveles de glucosa en sangre al aumentar la excreción de glucosa y disminuir la presión arterial a través de la natriuresis y la contracción del volumen plasmático. Debido a sus efectos beneficiosos, actualmente se utilizan en el tratamiento tanto de la diabetes mellitus como de la insuficiencia cardíaca, lo que ha llevado a un uso generalizado en los últimos años. En este artículo, presentamos el caso de un paciente que presentó una deshidratación hipernatrémica grave relacionada con el inicio del tratamiento con inhibidores de iSGLT2.

© 2025 Los Autores. Publicado por Iberoamerican Journal of Medicine. Éste es un artículo en acceso abierto bajo licencia CC BY (<http://creativecommons.org/licenses/by/4.0/>).

HOW TO CITE THIS ARTICLE: Alegre-González D, García-Guerreros S, Martínez-Hernández S, Brito-Díaz AY, Casañas-Martínez M, Baeza-Trinidad R. The Association of SGLT-2 inhibitors (Empagliflozin) with the development of hypernatremic dehydration: a case report. *Iberoam J Med.* 2025;7(1):25-28. doi: 10.53986/ibjm.2025.0001.

1. INTRODUCCIÓN

Sodium-Glucose-Cotransporter-2 inhibitors (SGLT2 inhibitors) are a family of oral antidiabetic drugs that were first marketed in 2010. These drugs reduce blood glucose levels by blocking glucose reabsorption in the proximal tubules, which are responsible for reabsorbing 90% filtered glucose, thereby increasing glucose excretion in the urine [1, 2]. Commonly used SGLT2 inhibitors include Empagliflozin, Dapagliflozin and Canagliflozin. Initially, SGLT2 inhibitors were used to decrease the blood glucose levels in patients with type 2 diabetes. However, some studies have demonstrated their cardiovascular benefits, including reducing blood pressure through natriuretic and plasma volume contraction and decreasing mortality in patients with heart failure. This has led to a significant increase in the use of SGLT2 inhibitors has increased in a wide range of different patients in recent years [1-3].

Hypernatremic dehydration is a medical condition characterized by elevated sodium levels, typically due to a deficit in body water. This condition can lead to symptoms such as extreme thirst and dry mucous membranes. In moderate to severe cases, hypernatremia can cause confusion and neurological symptoms, making it a potentially serious condition that requires prompt evaluation and treatment. [4-6].

To date, only four clinical cases have been published exploring the potential association between SGLT2 inhibitors and electrolyte disturbances. In two of these cases,

severe hypernatremia was reported in patients treated with empagliflozin and dapagliflozin [4, 7, 8].

2. CASE REPORT

A 73-year-old man with a history of type 2 diabetes mellitus, cerebral stroke 10 years ago and moderate cognitive impairment was admitted to the emergency department. The patient presented with three days of asthenia, drowsiness and decreased intake. He had no fever and there was no clinical evidence of infection. The patient had poor glycemic control over the last 48 hours. The patient had strong family support, residing at home with his wife and several caregivers, (ECOG scale 3) ensuring strict medication adherence and appropriate dietary intake. He maintained adequate hydration with 1 or 1.5 liters of fluid daily. The patient was on regular treatment with folic acid 5 mg once a day, Rivastigmine 9.5 mg patch, low molecular weight heparin 40 mg subcutaneous injection once daily, Sitagliptin 1000mg once a day and Metformin/Empagliflozin 1000mg/12.5mg twice a day for glycemic control.

On physical examination, signs of dehydration were observed in mucous membranes. The patient presented dysarthria and decreased level of consciousness during the interview, with no signs of neurological disease. Neck stiffness was not evident. Oxygen saturation, blood pressure and temperature were within normal ranges.

Laboratory tests revealed glucose 102 mg/dL (NR 100-125 mg/dL), pH 7.34 (NR 7.25-7.45), creatinine 1.53 mg/dL (NR 0.7-1.2 mg/dL) sodium 173 mmol/L (NR 135-148

mmol/L) potassium 4.3 mmol/L (NR 3,6-5,1 mmol/L) CRP 22 mg/dL (NR <10 mg/dL) Leukocyte count and liver profile were within normal ranges. Urine osmolality was 762 mmol/kg (NR 300-1300 mOsm/kg) urine sodium was 123mmol/L,urine potassium was 29 mmol/L, urine glucose levels were ≥ 500 mg/dL and ketones in urine were negative. The evolution of sodium, potassium and creatinine levels during the hospital stay are showed in Figure 1.

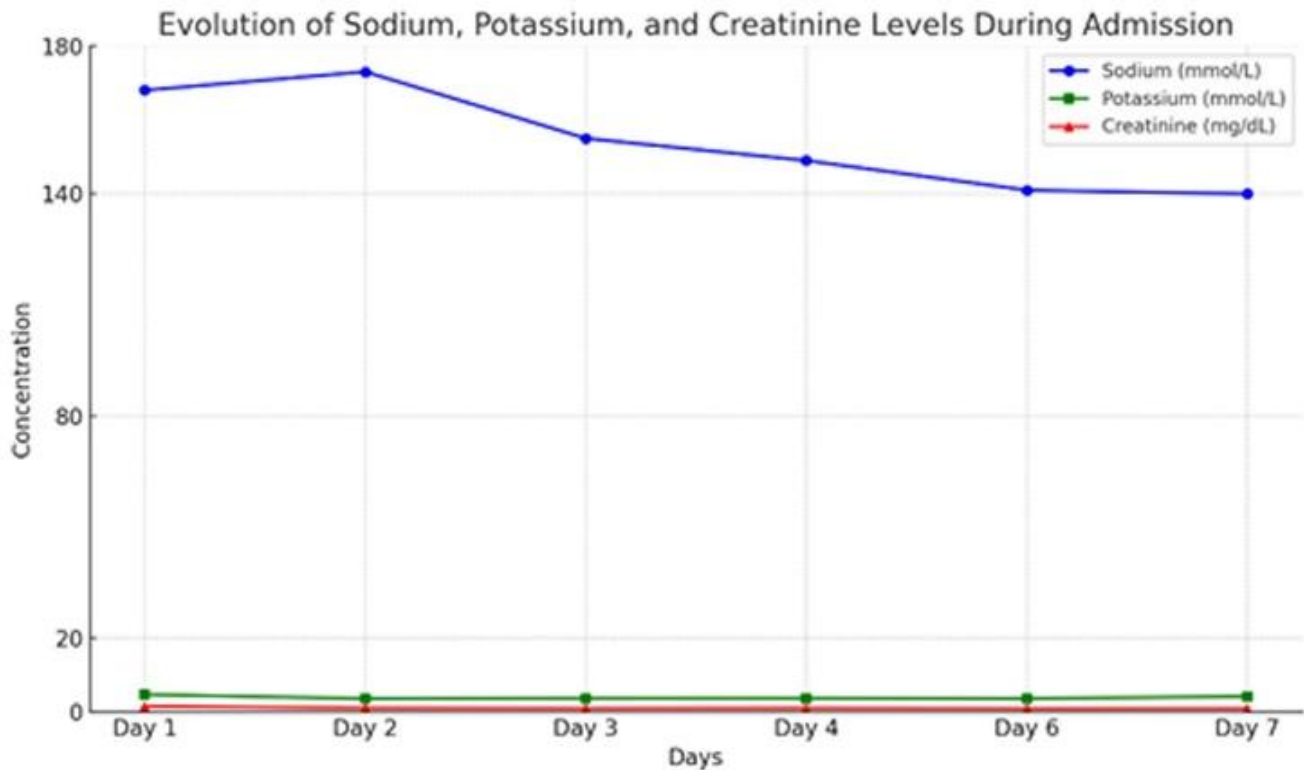


Figure 1: Evolution of sodium, potassium and creatinine levels throughout admission.

Treatment with Empagliflozin was introduced a moth before being admitted to the hospital. No other medications known to cause hypernatremia as an adverse reaction were identified.

Hypernatremic dehydration and prerenal kidney failure were confirmed. Fluid therapy with hypotonic fluids was initiated and Sitagliptin and Metformin/Empagliflozin treatment were discontinued.

By day 3, the patient had regained full consciousness and normal speech. On By day 5, kidney function and blood sodium levels had normalized. The patient was discharged on day 7 with normal blood and urine sodium levels and without neurological symptoms. Treatment with Metformin/Empagliflozin 1000/12.5mg was permanently discontinued and the patient has not experienced new episodes of dehydration to date.

3. DISCUSSION

SGLT2 inhibitors like Empagliflozin work by reducing blood glucose levels independently of insulin. They inhibit glucose reabsorption in the proximal tubules of the kidneys by blocking the renal SGLT2 receptor, increasing glucose excretion in the urine and reducing sodium absorption [1, 2]. The relationship between solute and water losses determines

the resulting changes in serum osmolality, sodium concentration and plasma volume contraction [3, 4]. Sustained glucosuria can result in significant electrolyte-free water loss due to the associated osmotic effect, reducing blood glucose levels but also potentially leading to long-term hypernatremia dehydration. [1, 2, 6].

However, this glycosuria effect added to reduction in sodium absorption associated with SGLT2 inhibitors may increase the risk of severe dehydration in susceptible patients. [2, 3, 6]. Risk factors for hypernatremia include dysregulation of the sensation of thirst, cognitive impairment, compromised kidney function and the use of other medications [4]. Elderly patients are at an increased risk of developing these types of electrolyte imbalances, due to not only dysregulation of thirst sensation and the higher like hood of renal insufficiency but also because of the polypharmacy, they often exhibit [4].

In the case of our patient, dehydration was excluded as the primary cause of hypernatremia based on normal creatinine

and urea levels along with well-hydrated skin and mucous membranes during the initial assessment. Caregivers confirmed adequate daily fluid intake, and there were no signs of digestive losses such as vomiting or diarrhea. Additionally, diuretic-induced hyponatremia was ruled out as the patient was not receiving any diuretic treatment. Diabetes insipidus was also excluded based on normal osmolality findings in the complementary tests, and the resolution of hyponatremia after discontinuation of the SGLT-2 inhibitor. Subsequent follow-up with normal serum sodium levels further confirmed the diagnosis.

The progressive increase in the use of SGLT2 inhibitors in elderly patients with evidence of heart failure, either individually or in combination with other diuretics, could potentially heighten the long-term risk of developing these types of electrolyte disorders, even in those patients without other risk factors for dehydration. [2, 3, 8].

4. CONCLUSIONS

The overall benefits of SGLT2 inhibitors in diabetes mellitus and cardiovascular risk are well established, and their safety and tolerability have been widely demonstrated. However, it is important to recognize that SGLT2 inhibitors can cause hyponatremic dehydration in susceptible patients. Given the progressive increase in the prescription of SGLT2 inhibitors, the potential development of electrolyte disturbances should be considered not only in elderly patients with high risk of dehydration and polypharmacy but also in those with adequate fluid intake who are undergoing treatment with SGLT inhibitors.

5. CONFLICT OF INTERESTS

The authors have no conflict of interest to declare. The authors declared that this study has received no financial support.

6. REFERENCES

1. Monica Reddy RP, Inzucchi SE. SGLT2 inhibitors in the management of type 2 diabetes. *Endocrine*. 2016;53(2):364-72. doi: 10.1007/s12020-016-0943-4.
2. Scheen AJ. Pharmacodynamics, efficacy and safety of sodium-glucose co-transporter type 2 (SGLT2) inhibitors for the treatment of type 2 diabetes mellitus. *Drugs*. 2015;75(1):33-59. doi: 10.1007/s40265-014-0337-y.
3. Kashiwagi A, Maegawa H. Metabolic and hemodynamic effects of sodium-dependent glucose cotransporter 2 inhibitors on cardio-renal protection in the treatment of patients with type 2 diabetes mellitus. *J Diabetes Investig*. 2017;8(4):416-27. doi: 10.1111/jdi.12644.
4. Gelbenegger G, Buchtele N, Schoergenhofer C, Roeggl M, Schwameis M. Severe Hyponatremic Dehydration and Unconsciousness in a Care-Dependent Inpatient Treated with Empagliflozin. *Drug Saf Case Rep*. 2017;4(1):17. doi: 10.1007/s40800-017-0058-8.
5. Molaschi M, Ponzetto M, Massaia M, Villa L, Scarafioti C, Ferrario E. Hyponatremic dehydration in the elderly on admission to hospital. *J Nutr Health Aging*. 1997;1(3):156-60.
6. Popli S, Tzamaloukas AH, Ing TS. Osmotic diuresis-induced hyponatremia: better explained by solute-free water clearance or electrolyte-free water clearance? *Int Urol Nephrol*. 2014;46(1):207-10. doi: 10.1007/s11255-012-0353-3.
7. Sugiyama J, Ryuge A, Mitsubayashi K, Ito M, Matsumoto N, Takeuchi R, et al. Dapagliflozin induced hyponatremia via osmotic diuresis: a case report. *CEN Case Rep*. 2024;13(1):9-13. doi: 10.1007/s13730-023-00790-x.
8. Kaur A, Winters SJ. Severe hypercalcemia and hyponatremia in a patient treated with canagliflozin. *Endocrinol Diabetes Metab Case Rep*. 2015;2015:150042. doi: 10.1530/EDM-15-0042.