



Case Report

Corynebacterium endocarditis in a patient with a cardiac implantable electronic device

Sevil Alkan ^{a,*} , Uğur Küçük ^b , Serpil Şahin ^c , Taylan Önder ^a 

^a Department of Infectious Diseases and Clinical Microbiology, Canakkale Onsekiz Mart University, Canakkale, Turkey

^b Department of Cardiology, Faculty of Medicine, Canakkale Onsekiz Mart University, Canakkale, Turkey

^c Department of Cardiovascular Surgery, Faculty of Medicine, Canakkale Onsekiz Mart University, Canakkale, Turkey

ARTICLE INFO

Article history:

Received 28 February 2022

Received in revised form 23

March 2022

Accepted 01 April 2022

Keywords:

Corynebacterium

Endocarditis

Cardiac implantable electronic device

ABSTRACT

Cardiac implantable electronic device (CIED) infections have been rising around the world. Many microorganisms can lead to this disease. *Corynebacterium* species are catalase-positive Gram-positive bacilli, also known as "diphtheroids" or "coryneform" bacteria, were once almost universally dismissed as contamination when recovered from patients, but they are now increasingly being linked to serious infections and have the ability to form biofilms and rarely cause CIED infections and this can be complicated as infective endocarditis. *Corynebacterium* spp. are frequently overlooked as contaminants in blood cultures, yet they can cause a serious infective endocarditis (IE). Antibiotic resistance is increasing among *Corynebacterium* spp., and this makes treatment more challenging. There are few reports of IE caused by *Corynebacterium* spp., and more research is needed. Here, we report a case of 55-year old man with *Corynebacterium* spp. cardiac device-related infective endocarditis.

© 2022 The Authors. Published by Iberoamerican Journal of Medicine. This is an open access article under the CC BY license (<http://creativecommons.org/licenses/by/4.0/>).

* Corresponding author.

E-mail address: s-ewil@hotmail.com

ISSN: 2695-5075 / © 2022 The Authors. Published by Iberoamerican Journal of Medicine. This is an open access article under the CC BY license (<http://creativecommons.org/licenses/by/4.0/>).

<https://doi.org/10.53986/ibjm.2022.0017>

Endocarditis por *Corynebacterium* en un paciente portador de un dispositivo electrónico cardíaco implantable

INFO. ARTÍCULO

Historia del artículo:

Recibido 28 Febrero 2022

Recibido en forma revisada 23

Marzo 2022

Aceptado 01 Abril 2022

Palabras clave:

Corynebacterium

Endocarditis

Dispositivos electrónicos

implantables cardíacos

RESUMEN

Las infecciones por dispositivos electrónicos implantables cardíacos (CIED) han ido en aumento en todo el mundo. Muchos microorganismos pueden conducir esta enfermedad. Las especies de *Corynebacterium* son bacilos grampositivos catalasa positivos, también conocidos como bacterias "difteroides" o "corineformes" que, alguna vez, se descartaron casi universalmente como contaminación cuando se recuperaron de los pacientes, pero ahora se los vincula cada vez más con infecciones graves y tienen la capacidad de formar biopelículas y rara vez causan infecciones por CIED, y esto puede complicarse como una endocarditis infecciosa. *Corynebacterium spp.* a menudo se pasan por alto como contaminantes en los hemocultivos, pero pueden causar una endocarditis infecciosa (EI) grave. La resistencia a los antibióticos está aumentando entre *Corynebacterium spp.*, y esto hace que el tratamiento sea más desafiante. Hay pocos informes de EI causada por *Corynebacterium spp.*, y se necesita más investigación. Aquí reportamos un caso de un hombre de 55 años con EI por *Corynebacterium spp.* relacionada con dispositivos cardíacos.

© 2022 Los Autores. Publicado por Iberoamerican Journal of Medicine. Éste es un artículo en acceso abierto bajo licencia CC BY (<http://creativecommons.org/licenses/by/4.0/>).

HOW TO CITE THIS ARTICLE: Alkan S, Küçük U, Şahin S, Önder T. *Corynebacterium* endocarditis in a patient with a cardiac implantable electronic device. *Iberoam J Med.* 2022;4(3):164-168. doi: 10.53986/ibjm.2022.0017.

1. INTRODUCTION

Corynebacterium spp. are aerobic, gram-positive rods, which are in normal skin flora bacteria in humans. It is also abundant in soils and waters. They can form biofilms and be found in the hospital environment, surfaces, and medical equipments [1]. They are frequently isolated in cultures, but they were previously often considered contaminants. However, they can sometimes cause nosocomial infections in both immunocompetent and immunocompromised patients [2]. Factors such as advanced age, frailty, chronic lung disease, immunosuppression, prolonged hospitalization, use of medical instruments are the reported risk factors. *Corynebacterium spp.* can be difficult to manage due to increased antibiotic resistance [1, 2].

Cardiac implantable electronic device (CIEDs) were discovered in the early 1960s, and the number of patients which CIED applied increasing year-by-year [3]. The total number of CIED installed per 1,000,000 people per year is 247, and with the aging of the population [4, 5]. It is predicted that these devices will be installed more and more in our country as in the world over the years [3].

CIED infections could be observed as pocket infections, occult bacteremia, and infective endocarditis (IE) (wire or cap). Pocket infections are the most common (60%) and local inflammatory changes in the pocket area (pain, redness, swelling, warmth, discharge or decomposition of

the overlying skin) could be observed [4, 5]. Sometimes, pocket infection could be accompanied by bacteremia. However, bacteraemia could be observed without signs of infection in the pocket area [3-5]. IE is the third clinical presentation, being observed in 10-23% of all CIED infections [3]. The prevalence of CIED infections in CIED recipients is nearly 5% within 3.5 years post implantation [6]. The rate of those associated with CIED among all IE cases is around 10% in our country and in the world [3]. *Corynebacterium spp.* with demonstrated biofilm forming ability has been associated with cardiac device-associated infective endocarditis and there are few cases in the literature [6-8].

Hereby, we report a case report of a 55-year old man with *Corynebacterium spp.* cardiac device-related infective endocarditis. With this rare case, we aimed to contribute to the literature and to present that blood culture growth, which is often overlooked, can be encountered with a complicated CIED infection.

2. CASE REPORT

A 55-year-old man presented to our hospital with a 20-day history of fever. He denied other symptoms such as dyspnea, chest pain, abdominal pain, cough, diarrhea, or dysuria. His past medical history was limited to having hypertension, congestive heart failure, history of coronary artery bypass

grafting surgery 2 years ago and placement of a biventricular pacemaker 6 months ago. On his clinical examination, vital signs were as follows: his temperature was 39°C, blood pressure 136/84 mm/Hg, heart rate was 108 beats/minute, respiratory rate 22/minute and oxygen saturation was 95% on room air. No murmur was detected. Peripheral signs of IE such as Janeway lesions, Splinter haemorrhage and Osler's nodules were absent. There were rales in both lung bases on lung auscultation. The remainder of his medical examination was unremarkable. Due to his personal medical history, a transthoracic echocardiography (TTE) was performed without vegetation detected.

The patient was hospitalized for further examination with a prediagnosis of IE. Since the patient did not have a clear focus of infection (he had no signs of pneumonia, urinary tract infection, etc., and other viral-zoonotic infections), IE was considered as a preliminary diagnosis because he only had a CIED as a risk factor. Initial laboratory studies showed a white blood count of $18.9 \times 10^9/L$, a haemoglobin level of 12.4 g/dL and a platelet count of 192,100 /L. Urine analysis was showed 2+ blood, protein 1+. Biochemical blood analysis showed: normal electrolytes, liver and kidney function test and C reactive protein (CRP) at 10.4 mg/dl. There was no serological test results for HIV, HBV, HCV, CMV or EBV infection. A chest X-ray had bilateral basal infiltration and intracardiac device (ICD) (Figure 1). Ceftriaxone 1x2 g/day intravenous (i.v.) was begun empirically after six bottles of blood cultures were obtained. The blood culture samples incubated to BACTEC 9240 (Becton Dickinson Instrument System, Sparks, USA) and in six of them *Corynebacterium spp.* grew up. Phoenix100™ performed identification of the microorganism (Becton Dickinson Instrument System, Sparks, USA). The antibiotic susceptibility of the microorganism was determined be sensitive to vancomycin and linezolid, and resistance to cephalosporins, penicillin, ciprofloxacin, tetracycline, meropenem, and clindamycin. Accordingly, ceftriaxone was stopped and vancomycin 1x2 g/day i.v. was started. The patient was consulted with cardiologist again with a prediagnosis of IE for trans-oesophageal echocardiography (TEE). The TEE revealed 0.9 mm dimensions mobile vegetation on the tricuspid valve anterior leaflet. After 72 hours of the treatment, surveillance blood cultures did not return negative. The CIED was removed and sent for culture and sensitivity. The same bacterial growth was obtained. After the removal of the CIED, the blood culture turned negative.

After a total of 6 weeks of vancomycin treatment, considering the significant improvement of the health conditions, the patient was discharged. One month after the

discharge, a transesophageal echocardiogram was performed and showed no vegetation of the valve leaflets and he did not report any complications. At the three-month follow-up, he was in good health, afebrile, and had not relapse.

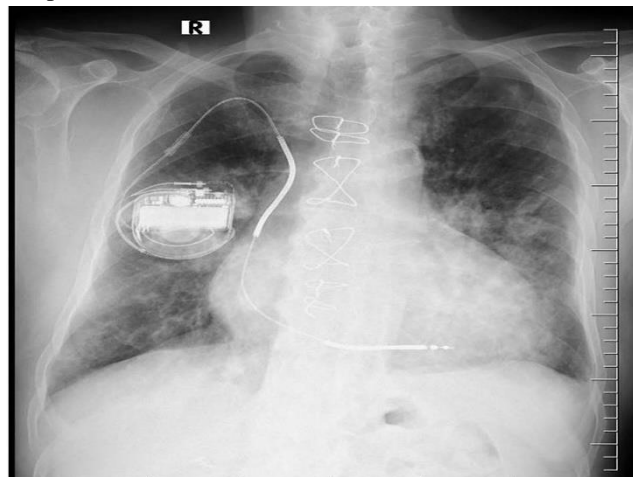


Figure 1: Chest x-ray showing the intracardiac device of the patient.

3. DISCUSSION

Permanent pacemaker (PPM), intracardiac defibrillator (ICD), and cardiac resynchronization therapy device (CRTD) are the most common CIEDs. The reported incidence of IE in patients with these devices is 0.5-5.7% and 1.8-10/1000 device year [9, 10]. Approximately 10% of all IE cases and in Turkey 7% of IE cases were reported to be associated with CIED [3]. The presented case had ICD associated IE. In 80% of IE cases, the causative agent is streptococci or staphylococci. Because of the increase in cases with health care associated infections in recent years, *Staphylococcus aureus* and coagulase-negative staphylococci (CNS) are more common agents while the proportion of viridans streptococci decreased relatively [3]. The patient we presented had CIED and was diagnosed as IE due to *Corynebacterium spp.*, *Corynebacterium* subtype classification could not be made.

Skin flora bacteria *Corynebacterium spp.* can cause IE, especially in the presence of artificial valves and other intracardiac devices. If they reproduce in all blood culture sets of patients who have been pre-diagnosed as having IE, it should be kept in mind that these microorganisms may also be causative, and the growth should not be considered contamination [3]. In the present case, *Corynebacterium spp.* grew in all (6/6) of the blood culture samples. He had no pocket infection findings.

The diagnosis of CIED-associated endocarditis is made by

the presence of vegetation at the tip of the wire in a patient with signs and symptoms of systemic infection, with or without pocket infection or bacteremia/fungemia [3]. The presented case had blood culture positivity and vegetation at the tricuspid valve (diagnosed with TEE). He also had fever as symptom of systemic infection.

TTE and TEE may not be sufficient to exclude CIED-associated endocarditis. According to the guideline, 18F-FDG PET/CT or SPECT/CT marked leukocyte scintigraphy should be requested to exclude CIED-associated endocarditis (3). The presented case's vegetation was detected in the TEE examination.

In previous studies *Corynebacterium spp.* have been associated with CIED-associated endocarditis [7, 8, 11-15]. In a study examining 30 IE episodes due to *Corynebacterium spp.*, the median age of the patients was 71 years and 77% of them were male. *C. striatum* (n=11) and *C. jeikeium* (n=5) were the most common species [12]. In the literature, *Corynebacterium spp.* were defined into subtypes by using the VITEK 2 Compact (Biomerieux, France) automated system and the 16S rDNA sequence analysis methods [7, 8, 11-15]. Our patient was a 55-year old man and the subspecies analysis could not be performed because such examinations could not be performed in our center.

Multidrug-resistant *C. striatum* infections have occurred in patients who have been in the hospital for a long time and have been exposed to broad-spectrum antibiotics, as well as in patients who have intracardiac or endovascular devices, or who are immunocompromised [11]. Our patient was not immunocompromised and had an ICD. He also had no history of hospitalisation or antibiotic use. The antibiotic susceptibility of the microorganism was determined be sensitive to vancomycin and linezolid.

The duration of the treatment should be 2-4 weeks in wire endocarditis and 4-6 weeks in valve endocarditis with the removal of the device. In the treatment of septic patients with unstable hemodynamics, gentamicin, cefepime, or meropenem may be added to vancomycin treatment [3]. The presented case was treated with vancomycin for 6 weeks, and the device was removed.

4. CONCLUSIONS

The presented case is a rare *Corynebacterium spp.* cardiac device-related infective endocarditis case. *Corynebacterium spp.* are usually overlooked as contaminants in blood cultures, but they can also cause IE, which is a serious disease, especially in patients with cardiac devices. *Corynebacterium spp.* are becoming increasingly resistant

to antibiotics, making treatment more difficult. In order to cure the patient, the infected devices needs also be removed. Furthermore, IE can be misdiagnosed using TTE, necessitating the use of further diagnostic procedures such as TEE. There are few reports of CIED caused by *Corynebacterium spp.*, and more research is needed. This report demonstrated the importance of repeating blood cultures and TEE, for the diagnosis of CIED.

5. CONFLICT OF INTERESTS

The authors have no conflict of interest to declare. The authors declared that this study has received no financial support.

6. REFERENCES

1. Zasada AA, Mosiej E. Contemporary microbiology and identification of *Corynebacteria spp.* causing infections in human. *Lett Appl Microbiol.* 2018;66(6):472-83. doi: 10.1111/lam.12883.
2. Bernard K. The genus *corynebacterium* and other medically relevant coryneform-like bacteria. *J Clin Microbiol.* 2012;50(10):3152-8. doi: 10.1128/JCM.00796-12.
3. Şimşek-Yavuz S, Akar AR, Aydoğdu S, Berzeg Deniz D, Demir H, Hazırolan T, et al. Diagnosis, treatment and prevention of infective endocarditis: Turkish consensus report-2019. *Türk Kardiyol Dern Ars.* 2020;48(2):187-226. English. doi: 10.5543/tkda.2020.89689.
4. Kusumoto FM, Schoenfeld MH, Wilkoff BL, Berul CI, Birgersdotter-Green UM, Carrillo R, et al. 2017 HRS expert consensus statement on cardiovascular implantable electronic device lead management and extraction. *Heart Rhythm.* 2017;14(12):e503-e551. doi: 10.1016/j.hrthm.2017.09.001.
5. Bongiorno MG, Tascini C, Tagliaferri E, Di Cori A, Soldati E, Leonildi A, et al. Microbiology of cardiac implantable electronic device infections. *Europace.* 2012;14(9):1334-9. doi: 10.1093/europace/eus044.
6. Jędrzejczyk-Patej E, Mazurek M, Kowalski O, Sokal A, Koziel M, Adamczyk K, et al. Device-related infective endocarditis in cardiac resynchronization therapy recipients - Single center registry with over 2500 person-years follow up. *Int J Cardiol.* 2017;227:18-24. doi: 10.1016/j.ijcard.2016.11.029.
7. Melo N, Correia C, Gonçalves J, Dias M, Garcia RM, Palma P, et al. *Corynebacterium striatum* cardiac device-related endocarditis: A case report. *IDCases.* 2021;27:e01371. doi: 10.1016/j.idcr.2021.e01371.
8. Serpa Pinto L, Dias Frias A, Franca M. *Corynebacterium striatum* Cardiac Device-Related Infective Endocarditis: The First Case Report in a Patient With a Cardiac Resynchronization Therapy Defibrillator Device and Review of the Literature. *J Med Cases.* 2021;12(2):61-4. doi: 10.14740/jmc3618.
9. Sandoe JA, Barlow G, Chambers JB, Gammage M, Guleri A, Howard P, et al. Guidelines for the diagnosis, prevention and management of implantable cardiac electronic device infection. Report of a joint Working Party project on behalf of the British Society for Antimicrobial Chemotherapy (BSAC, host organization), British Heart Rhythm Society (BHRS), British Cardiovascular Society (BCS), British Heart Valve Society (BHVS) and British Society for Echocardiography (BSE). *J Antimicrob Chemother.* 2015;70(2):325-59. doi: 10.1093/jac/dku383.
10. Johansen JB, Jørgensen OD, Møller M, Arnsbo P, Mortensen PT, Nielsen JC. Infection after pacemaker implantation: infection rates and risk factors associated with infection in a population-based cohort study of 46299

consecutive patients. *Eur Heart J.* 2011;32(8):991-8. doi: 10.1093/eurheartj/ehq497.

11. Biscarini S, Colaneri M, Mariani B, Pieri TC, Bruno R, Seminari E. A case of *Corynebacterium striatum* endocarditis successfully treated with an early switch to oral antimicrobial therapy. *Infez Med.* 2021;29(1):138-44.

12. Gupta R, Popli T, Ranchal P, Khosla J, Aronow WS, Frishman WH, et al. *Corynebacterium Jeikeium* Endocarditis: A Review of the Literature. *Cardiol Rev.* 2021;29(5):259-62. doi: 10.1097/CRD.0000000000000355.

13. Bläckberg A, Falk L, Oldberg K, Olaison L, Rasmussen M. Infective Endocarditis Due to *Corynebacterium* Species: Clinical Features and

Antibiotic Resistance. *Open Forum Infect Dis.* 2021;8(3):ofab055. doi: 10.1093/ofid/ofab055.

14. Abi R, Ez-Zahraoui K, Ghazouani M, Zohoun A, Kheyl J, Chaib A, et al. [A *Corynebacterium striatum* endocarditis on a carrier of pacemaker]. *Ann Biol Clin (Paris).* 2012;70(3):329-31.. doi: 10.1684/abc.2012.0707.

15. Oliva A, Belvisi V, Iannetta M, Andreoni C, Mascellino MT, Lichtner M, et al. Pacemaker lead endocarditis due to multidrug-resistant *Corynebacterium striatum* detected with sonication of the device. *J Clin Microbiol.* 2010;48(12):4669-71. doi: 10.1128/JCM.01532-10.